


PATIENT

Darbie Martin

PRESENTING CLINICAL SIGNS

History: Progressive heart murmur, now grade 3/6. Cough when excited.

SPECIES

Canine

BREED

Affenpinscher

SEX

Female Spayed

ECHOCARDIOGRAM FINDINGS

2D, m-mode, color flow and doppler imaging is available. Diffuse thickening of mitral valve leaflets (anterior>posterior) with mild prolapse into the left atrial lumen. Moderate eccentric mitral regurgitation with moderate left atrial dilation. Normal MR velocity. Mildly increased LV diameter with hyperdynamic myocardial function. The tricuspid valve appears subjectively normal, with trace tricuspid regurgitation. Normal velocity. Normal right atrial and ventricular diameter. The pulmonic and aortic valves are normal in morphology and mobility. Normal pulmonic and aortic outflow velocities. No aortic or pulmonic insufficiency. No pericardial or pleural effusion noted. No cardiac tumors observed.

CARDIAC CHART
AGE

10 years

WEIGHT

12.8lbs

INTERPRETED BY

 Maggie Machen Lamy,
 DVM DACVIM
 (Cardiology)

IMAGING
PERFORMED BY

Crystal Hill, RVT

HOSPITAL NAME

 New Hamburg Vet
 Clinic

CANINE CARDIAC PARAMETERS	MR VMAX (m/s)	TR VMAX (m/s)	LA/AO (Boon method)	LA/AO (Heart Base; Swe)	FS (%)	EF (%)	EPSS (cm)
NORMAL PARAMETER	4.5-5.5	<2.7	1.3	<1.6	28-40	40-100	<0.6
PATIENT	4.9	2.0	1.5	1.8	39	72	0.27
CANINE CARDIAC PARAMETERS	HR (BPM)	AV VMAX (m/s)	PV MAX (m/s)	BODY WEIGHT (kg)	LA 2D short axis Base view (cm)	LVIDd Avg; 2D and m-mode short axis (cm)	LVIDs Avg; 2D and m-mode short axis (cm)
NORMAL PARAMETER	50-100	0.7-1.7	0.7-1.6	BELOW	BELOW	BELOW	BELOW
PATIENT	171	1.5	0.8	5.8	2.8	3.6	1.7
*Normal chamber parameters expressed as a mean value (SD)				3	1.27 (5.3)	2.46 (2.46)	1.36 (5.5)
BODY WEIGHT DEPENDENT PARAMETERS				5	1.40 (4.5)	2.74 (5.2)	1.60 (4.7)
<i>*Note: All measurements based upon multi-modal images and methods. An average value is reported.</i>				10	1.50 (3.8)	3.27 (3.5)	2.06 (3.1)
				15	1.83 (2.0)	3.71 (2.4)	2.43 (2.1)
				20	2.02 (1.9)	4.14 (2.2)	2.80 (2.0)
				25	2.18 (2.4)	4.48 (2.9)	3.10 (2.5)
				30	2.33 (3.3)	4.83 (3.9)	3.39 (3.4)
				35	2.48 (4.3)	5.17 (5.0)	3.69 (4.5)
				40	2.62 (5.2)	5.48 (6.1)	3.96 (5.4)
				50	2.88 (7.1)	6.07 (8.3)	4.46 (7.4)

INTERPRETATION OF THE FINDINGS & FURTHER RECOMMENDATIONS

Chronic degenerative valve disease causing moderate mitral and trace tricuspid regurgitation. Moderate left atrial enlargement indicates there is relatively low risk for imminent complication; however, risk for progression to spontaneous congestive heart failure in the future is elevated. No additional issues are identified.

REFERRING VET

NP

INVOICE

28350

DATE

1/16/23

Given the risk for progression and results of the EPIC trial, Pimobendan is indicated in this patient as below. Assessment of progression in the future will help predict long term outcome; however, prognosis is guarded at this stage (B2).



PATIENT

Darbie Martin

SPECIES

Canine

BREED

Affenpinscher

SEX

Female Spayed

AGE

10 years

WEIGHT

12.8lbs

INTERPRETED BY

Maggie Machen Lamy,
DVM DACVIM
(Cardiology)

IMAGING PERFORMED BY

Crystal Hill, RVT

HOSPITAL NAME

New Hamburg Vet
Clinic

REFERRING VET

NP

INVOICE

28350

DATE

1/16/23

While mainstem bronchi compression may certainly be contributing to a chronic increase in coughing, other primary airway contributions should also be considered (tracheal collapse, COPD/chronic bronchitis, etc). Screening chest radiographs are recommended. Consider hydrocodone for any mechanical component due to cardiomegaly. Chronic respiratory signs can lead to development of pulmonary hypertension if poorly controlled. Monitor for signs of this development, such as exertional syncope or collapse.

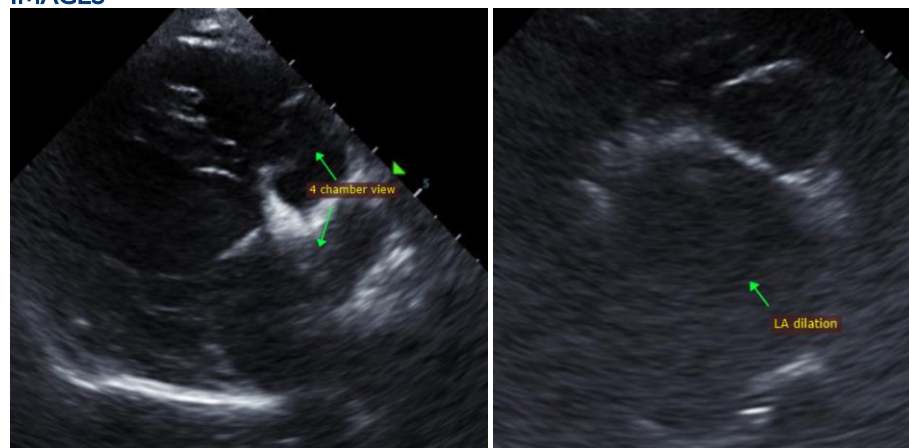
Omega fatty acid supplementation and mild salt restriction may also be of some long term benefit. Monitor for development of a progressive cough, labored breathing, exercise intolerance or collapse episodes.

Once on the medication for 3-5 days, anesthetic risk is considered mildly elevated. Cardiac protective drug choices (opioid/benzodiazepine premedication, Propofol or alfaxalone induction, iso or sevo gas) are recommended. Monitor for arrhythmias, hypotension, and hypoxia both intra and post-operatively and intervene as necessary. Judicious IV fluid rates are recommended to avoid fluid overload. Avoid heart rate stimulating drugs such as atropine unless clinically indicated.

Plan: Baseline BP/CXR recommended. Institute heart muscle support Pimobendan 0.3mg/kg PO q12h. Consider hydrocodone as discussed.

Recommend monitor for progression with a recheck echocardiogram in 6 months, sooner if any development of clinical signs.

IMAGES



The information and recommendations provided are based on the images presented by the referring veterinarian. No evaluation can be communicated regarding pathology that was not visible in the image/video clips provided.

Thank you for this referral. This report was generated using transcription software, and minor dictation errors may be present. If the clinical or image interpretation does not parallel your findings or if I can be of any further assistance, please contact me.

Maggie Machen Lamy, DVM
Diplomate of the American College of Veterinary Internal Medicine (Cardiology)
info@sonopath.com